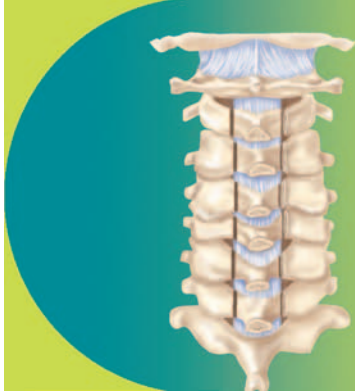

## PROCEDURE 24



# Complete Vertebral Resection for Primary Spinal Tumors

*Rick C. Sasso and Paul Kraemer*

### INDICATIONS PITFALLS

- Complete vertebral resection is indicated only for confirmed primary tumors without distant spread, and some isolated metastasis (i.e., renal cell).
- Complete vertebral resection is contraindicated in tumors with multiple skip lesions.
- Contiguous involvement of more than three vertebrae is a relative contraindication for complete vertebral resection.

### TREATMENT OPTIONS

- Careful preoperative planning includes reviewing the relative positions of the arterial, venous, or other soft tissue structures at the involved level.
- Preoperative embolization of bilateral segmental arteries at the effected level, and consider levels cephalad and caudal, reduce blood flow to the involved vertebra by 75% without influencing spinal cord evoked potentials, thus decreasing intraoperative hemorrhage.

### POSITIONING PEARLS

- Ensure the eyes are free of any external compression.
- Suspending the abdominal reduces venous plexus filling around the spinal cord and reduces intraoperative blood loss.

### POSITIONING EQUIPMENT

- A specialized table such as a Jackson table can be used to allow freedom of the chest and abdominal walls.

### Indications

- Malignant or locally aggressive benign primary spinal tumors
- Intracompartmental lesions involving the vertebral body and extending into the pedicles and posterior elements (Weinstein-Boriani-Biagini (WBB): zones 1-12, layers B and C)
- Extracompartmental lesions with only epidural or paravertebral extension (WBB: zones 1-12, layers A and D)
- Lesions without spread to or invasion of adjacent viscera, with only minimal adhesion to the vena cava or aorta
- Solitary metastatic lesions without extension to the paraspinous area

### Examination/Imaging

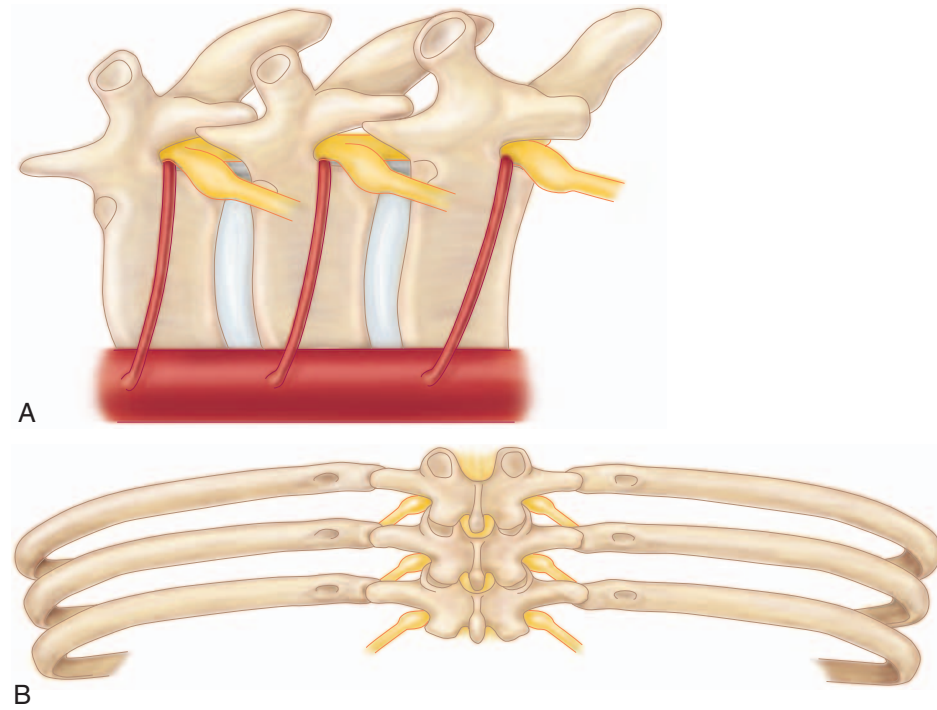
- Preoperative magnetic resonance imaging (MRI) is needed for proper tumor staging.
- Preoperative computed tomography (CT) is needed to confirm absence of distant metastasis.
- MRI is also crucial for identification of vulnerable vascular anatomy and appropriate preoperative planning.

### Surgical Anatomy

- The thoracic aorta is in intimate contact with the anterior vertebral column distal to T5 and must be carefully dissected and retracted anteriorly prior to resection of the involved vertebra. The aorta is less likely to be damaged from T1 to T4.
- The thoracic segmental arteries surrounding the involved vertebra must be identified and ligated. Variability has been reported in the anatomy of the segmental vasculature, including originating off the intercostal, and complete absence.
- The nerve root exiting cephalad to and crossing the body of the involved vertebra must be identified and ligated to facilitate the en bloc corpectomy (Figure 24-1, A and B).

### Positioning

- Position the patient prone on the operating table (Figure 24-2).
- Bolsters should be placed longitudinally on each side of the patient such that the anterior chest wall and abdominal wall clear the operating table.



B  
FIGURE 24-1

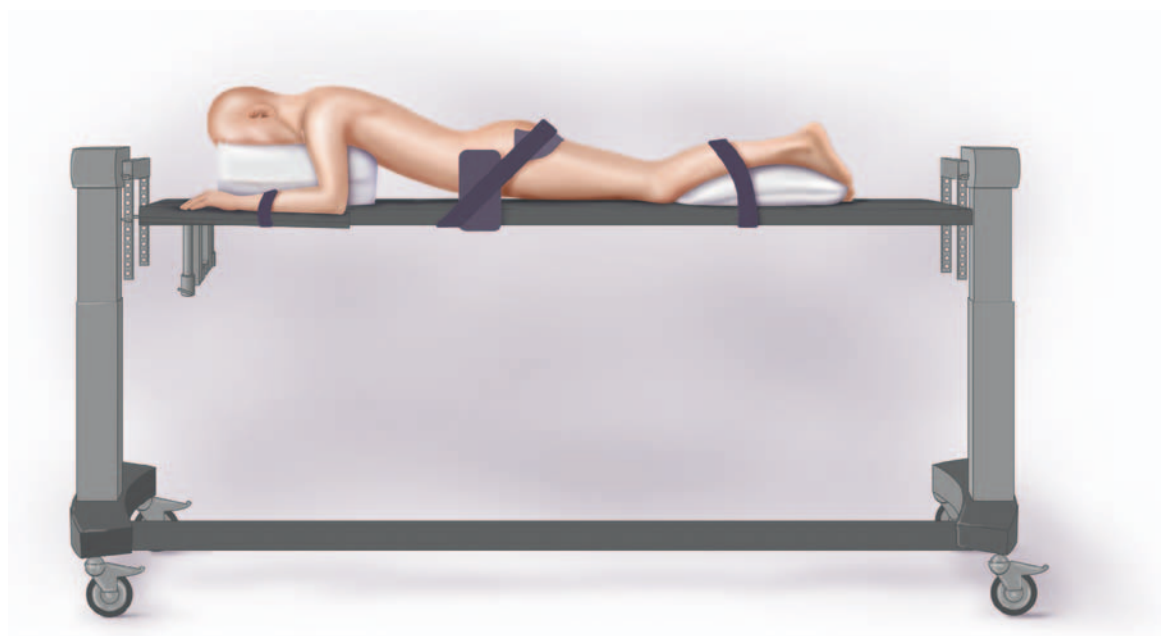


FIGURE 24-2

234 Procedure 24 | Complete Vertebral Resection for Primary Spinal Tumors

**PORTALS/EXPOSURES PEARLS**

- Dissection must be wide enough to fully expose the transverse processes bilaterally and extend well onto the ribs at the involved level.

**PORTALS/EXPOSURES PITFALLS**

- If patient underwent percutaneous biopsy, the biopsy tracts must be débrided at this time to prevent tumor contamination

**PORTALS/EXPOSURES CONTROVERSIES**

- Some authors recommend a second, anterolateral approach and thoracotomy to facilitate the ventral release in tumors with soft tissue extension.
- Alternatively, thoracoscopy has been used to facilitate ventral release and anterior column reconstruction with less morbidity than traditional thoracotomy.

**STEP 1 PEARLS**

- Because of the unique three-dimensional anatomy of the spine, a thread-wire saw or Gigli saw is a critical instrument in making the pedicle cuts.
- Use of a malleable thread-wire saw guide to pass the saw will protect the neural elements.

**STEP 1 PITFALLS**

- Once the spinal canal is breached, bleeding can be brisk. It is therefore imperative that all instrumentation is applied in advance so that the procedure can proceed with speed and efficiency.

**STEP 1 INSTRUMENTATION/IMPLANTATION**

- The rods used for provisional fixation should have a large lateral bend so as not to obstruct the operative field.

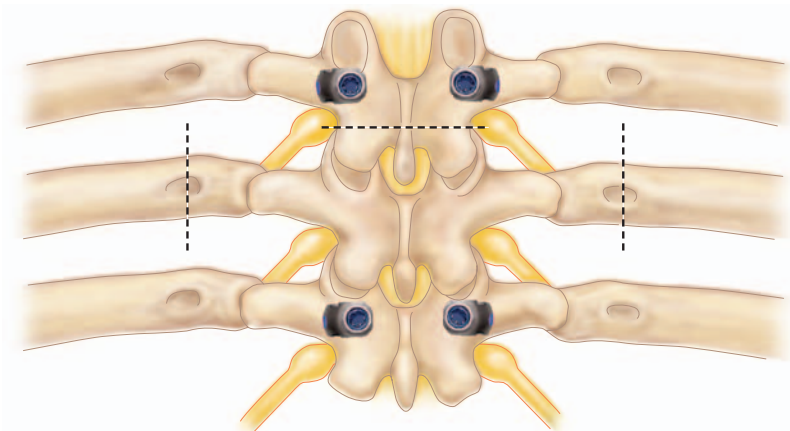


FIGURE 24-3

**Portals/Exposures**

- This procedure is ideally performed through a single, posterior approach.
- Make a vertical midline incision centered over the involved spinous process, extending one to three vertebrae caudal and cephalad.
- Dissect the paraspinal muscles from the spinous processes and lamina at all levels, and retract laterally.

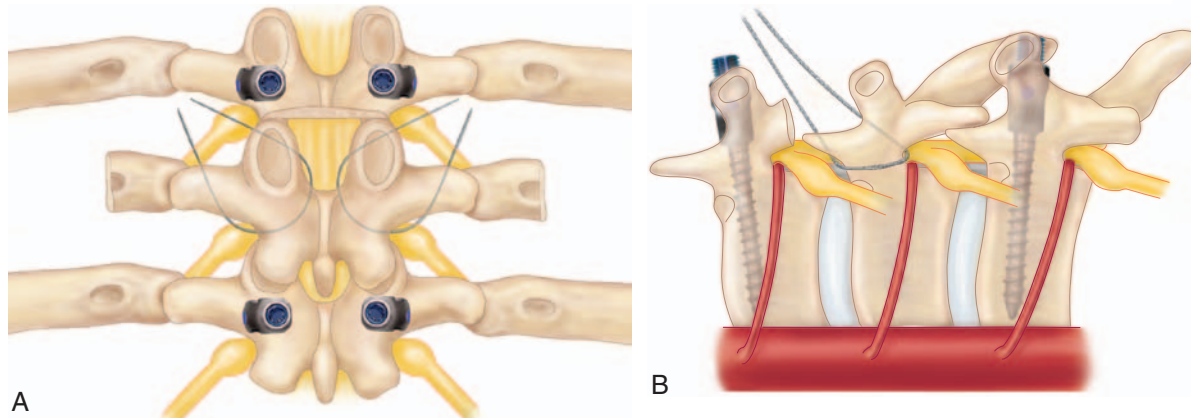
**Procedure**

**Step 1: En Bloc Laminectomy**

- Place pedicle screws in the vertebrae caudal and cephalad to the involved vertebra in preparation for posterior instrumentation (Figure 24-3). Additional levels may be instrumented at the surgeon's discretion, based on bone quality, spinal level, and body habitus.
- Transect the ribs of the involved vertebra 3 to 4 cm lateral to the costotransverse joint, and bluntly dissect the pleura from the vertebra.
- Remove the spinous process and inferior articular processes of the cephalad vertebra to expose the superior articular process of the involved vertebra.
- Pass the thread-wire saw from the medial cortex of the lamina through the intervertebral foramen in a cephalocaudal direction (Figure 24-4, A).
- Place the lateral end of the thread-wire saw beneath the superior articular process and the transverse process to wrap the saw around the pedicle.
- While applying force in a cephalad direction, use a reciprocating motion of the saw to cut the pedicle from caudal to cephalad (Figure 24-4, B).
- Repeat the above process to cut the contralateral pedicle, and remove the posterior elements (spinous process, superior articular processes, inferior articular processes, transverse processes, and pedicles) as a single unit (Figure 24-5).
- Apply provisional posterior fixation.

**Step 2: En Bloc Corpectomy**

- Bluntly dissect around the vertebral body, identifying the segmental arteries bilaterally.
- Ligate and divide the spinal branch of the segmental artery of the involved vertebra (Figure 24-6).
- Cut the nerve root, crossing the involved vertebral body on the side from which the vertebral body will be removed.



A  
FIGURE 24-4

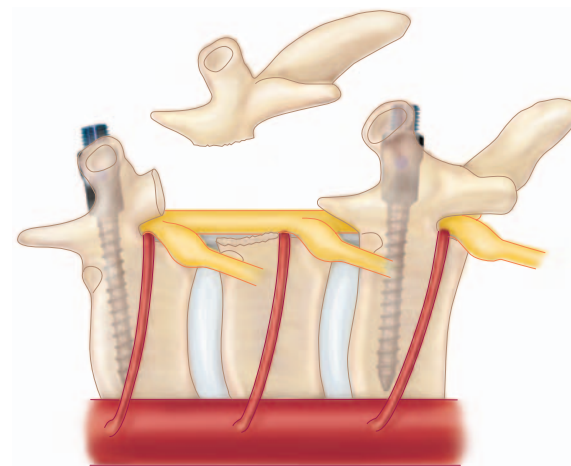


FIGURE 24-5

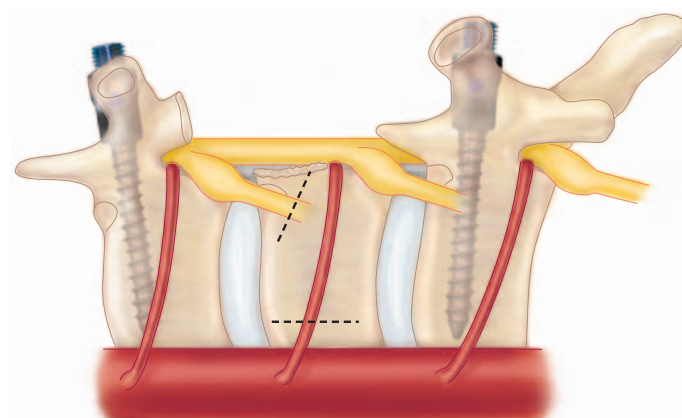


FIGURE 24-6

236 Procedure 24 | Complete Vertebral Resection for Primary Spinal Tumors

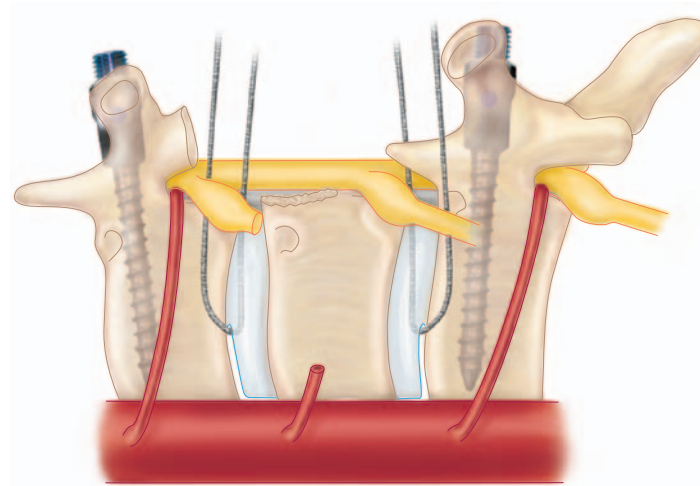


FIGURE 24-7

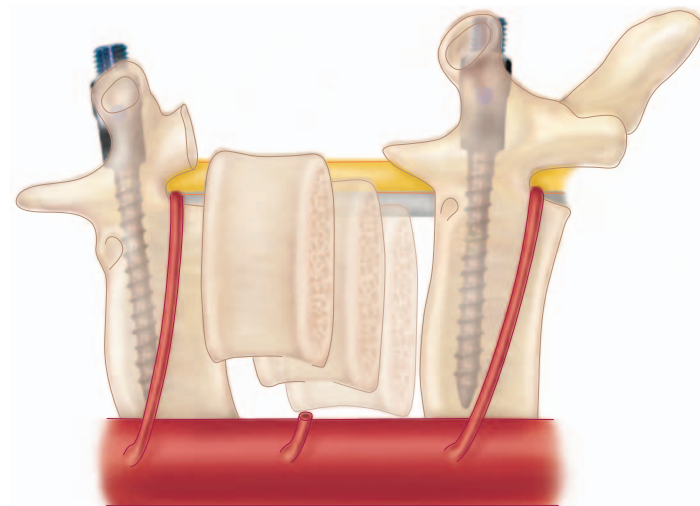


FIGURE 24-8

### STEP 2 PITFALLS

- Be sure to fully release all soft tissue structures, especially on the contralateral side of the nerve root transection.
- Because the vertebral body cuts are made directed at the spinal cord, it is imperative to protect the spinal cord with instruments such as spatulas or malleable retractors.

- Bluntly dissect laterally and anteriorly to develop the plane between the vertebral body and the pleura.
- Dissect the aorta from the anterior aspect of the vertebral body.
- Pass thread-wire saws anterior to the vertebral body.
- Mobilize the spinal cord by blunt dissection.
- Make vertebral body cuts with the thread-wire saws through the inferior end plate of the cephalad vertebra and the superior end plate of the caudal vertebra (Figure 24-7).
- Rotate the vertebral body around the spinal cord and remove it en bloc (Figure 24-8).

### Step 3: Anterior Reconstruction and Posterior Stabilization

- Insert cage to reconstruct the anterior column (Figure 24-9).
- Remove rods used for provisional fixation and apply rods to previously inserted pedicle screws for final fixation.

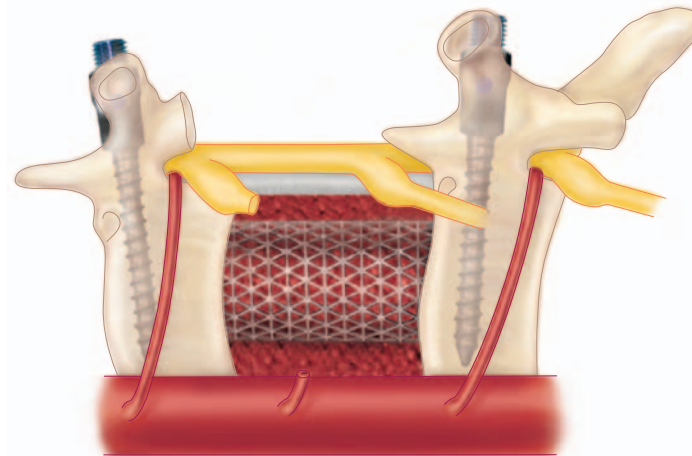


FIGURE 24-9

## Postoperative Care and Expected Outcomes

- Insert deep drains and apply suction for 2 to 3 days.
- Keep the patient in the intensive care unit (ICU) for 24 hours if there is significant blood loss or hypotension.
- The patient should be fitted for and wear a thoracolumbosacral orthosis for 2 to 3 months.

## Evidence

Boriani S, Weinstein JN, Biagini R. Primary bone tumors of the spine: terminology and surgical staging. *Spine* 1997;22:1036-44.

*This review article describes the Weinstein-Boriani-Biagnini (WBB) Surgical Staging System for primary spinal tumors. The WBB system provides a consistent method for classifying and planning the resection of tumors involving the unique three-dimensional anatomy of the vertebra.*

Kawahara N, Tomita K, Baba H, et al. Cadaveric vascular anatomy for total en bloc spondylectomy in malignant vertebral tumors. *Spine* 1996;21:1401-7.

*This cadaveric study characterized the vascular anatomy around the spine. The thoracic aorta is in direct contact with the anterior vertebral column. Furthermore, variability in the segmental arteries has been reported. Therefore familiarity with the vascular anatomy around the involved level as well as careful dissection is critical when performing complete vertebral resection.*

Nambu K, Kawahara N, Kobayashi T, et al. Interruption of the bilateral segmental arteries at several levels: influence on vertebral blood flow. *Spine* 2004;29(14):1530-4.

*This Level I study, using a dog model, demonstrated that embolization of bilateral segmental arteries at the affected level, as well as the levels cephalad and caudal, reduces blood flow to the involved vertebra by 75% without influencing spinal cord evoked potentials. Therefore preoperative embolization may be a safe and effective means of decreasing intraoperative hemorrhage.*

Tomita K, Kawahara N, Baba H, et al. Total en bloc spondylectomy: a new surgical technique for primary malignant vertebral tumors. *Spine* 1997;22(3):324-33.

*This Level IV study describes the surgical technique of complete vertebral resection used by Tomita and colleagues. The study reports the results of this technique in seven patients. Primary spinal tumors are relatively rare; therefore higher quality evidence is unavailable.*

Van Dijk M, Cuesta MA, Wuisman PIJM. Thoracoscopically assisted total en bloc spondylectomy: two case reports. *Surgical Endosc* 2000;14:849-52.

*This Level IV study describes thoracoscopically assisted ventral release and anterior column reconstruction as a safer alternative to traditional thoracotomy. The small number of subjects limits the quality of this study.*



## AUTHOR QUERY FORM

Dear Author

During the preparation of your manuscript for publication, the questions listed below have arisen. Please attend to these matters and return this form with your proof.

Many thanks for your assistance.

Query References	Query	Remarks
1	AU: This entry is not clear, especially with the inclusion of the word “consider”. Pls. clarify and make this a complete sentence as the previous bullet.	
2	AU: It’s not clear what “originating off the intercostal” (what?) and “complete absence” (of vasculature?) refer to. Pls. clarify.	